



Renato Ambrósio



Michael Belin

The BAD may be better for detecting ectatic disease and its susceptibility

Roibeard O'hEineachain
in Barcelona

A NEW software adaptation to the Pentacam Scheimpflug Tomography (Oculus) called the Belin/Ambrósio Enhanced Ectasia Display (BAD) has been demonstrated as more sensitive than standard techniques in the detection of keratoconus and subclinical ectasia in candidates for corneal refractive surgery, while also providing the “all-clear” in individuals who might otherwise have been unnecessarily deemed unsuitable for such procedures, said Renato Ambrósio MD PhD, Rio De Janeiro, Brazil.

“Ectasia may occur after LASIK despite low risk scores based on standard screening tests with Placido topography of the surface curvature, central single point ultrasound pachymetry and on surgical factors such as the depth and size of the ablation and the residual stromal bed thickness. In contrast, some cases with recognised risk factors are stable many years after LASIK. These are the mysteries of such rare but very severe complications,” Dr Ambrósio told the XXVII Congress of the ESCRS.

The BAD software combines both the anterior and posterior elevation data and pachymetric data to provide a three-dimensional tomographic representation of the cornea's shape, he said. It therefore overcomes some of the limitations of classic Placido topography and ultrasound central corneal thickness measurements, he added.

Enhanced sensitivity and specificity

He noted that his research indicates that the thickness profile provided by the Pentacam and the BAD software can detect early keratoconus with a sensitivity and specificity of 98 per cent. His findings also suggest it has a particular advantage when diagnosing the cases which conventional techniques of eyes fail to detect the condition, he said.

For example, in one study, conducted by his associate Marcella Salomão MD, the combination of tomographic thickness profiles and elevation data enabled the detection of abnormalities in the contralateral eyes of 47 of 48 patients with what at first appear to be unilateral but were demonstrated as very asymmetric keratoconus. This was the basis for developing the BAD software.

“These cases are not truly unilateral since the disease is considered bilateral by definition. What happens in such cases is that there are ectatic characteristics on the back elevation and thickness profile but no phenotypical expression of ectasia on the surface (yet). These observations were the basis for defining the characteristics of ectasia susceptibility. Some cases may also present with topographic abnormalities and are considered as forme fruste keratoconus. I would rather consider such cases as sub-clinical keratoconus. But, more importantly

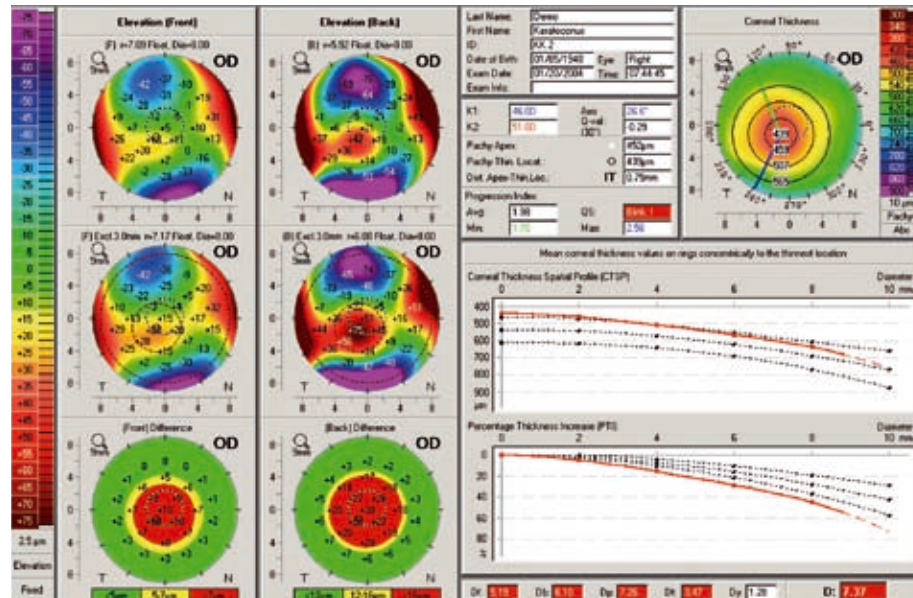


Figure BAD. The Belin/Ambrósio Display (BAD) of a patient (OD) with moderately advanced keratoconus. The four of the five parameters [Df (front elevation), Db (back elevation), Dp (pachymetric progression) and Dt (corneal thinnest point)] are all well outside the normal range with Standard Deviations ranging from 3.47 to 7.26. Because the cone is relatively central, the thinnest point displacement is within normal limits at 1.28 SD from the norm. The final “D” reading which represents a total analysis based on a regression analysis is highly abnormal at 7.37 SD from the norm

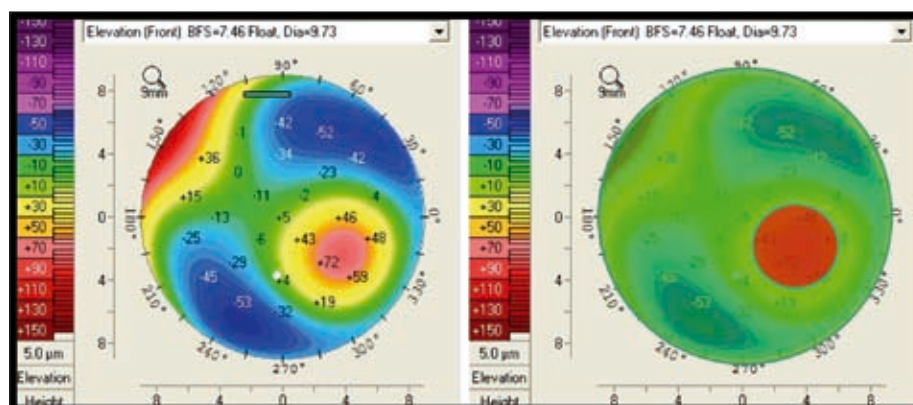


Figure B1. The left side of this display shows a prominent cone on the anterior elevation map. The right side shows the exclusion zone which is a 3.50mm circular area centered on the thinnest portion of the cornea. This exclusion zone encompasses the major part of the cone

than a nomenclature revision that is needed, we need to develop more specific analysis to separate the cases with suspicious topography that can benefit from refractive surgery,” he noted.

Dr Ambrósio illustrated with case studies of patients which demonstrated the increased sensitivity of the new technologies for detecting subclinical keratoconus in contralateral unoperated eyes of patients with unexplained LASIK ectasia, and other cases where it showed increased specificity in distinguishing cases of true ectasia from those with non ectatic asymmetric bow-tie astigmatism with inferior steepening and those with normal thin corneas.

“In addition to the detailed information based on tomography, corneal biomechanics assessment provides the enhanced screening approach, so that we can identify ectasia susceptibility, and this is what is relevant to refractive surgeons when they are assessing

a patient's suitability for surface ablation or LASIK,” he added.

Thickness profiles and enhanced best-fit sphere

The BAD display's software compares a patient's change of corneal thickness between the central and peripheral cornea with that of a standard database of controls and keratoconus cases, Dr Ambrósio explained. Eyes with keratoconus or subclinical ectasia tend to have a steeper reduction in their corneal thickness from the periphery to the centre, he said.

“The parameters of the Ambrósio Pachymetric Profiles are corneal thickness spatial profile and the percentage increase in thickness from the centre to the periphery (CTSP and PTI). They are based on the physiologic concept that the cornea is a meniscus, which is thinner in the centre and

thicker in the periphery. The idea is to detect the thinnest point and calculate the rate of increase in thickness from this point outwards to the periphery,” Dr Ambrósio said.

The software analyses a range of factors and yields a value for the cornea's degree of risk for ectasia. The values assessed include the deviations from the mean of the front and the back surface, the pachymetric progression, the thinnest point, and the displacement from the centre of the thinnest point. A sixth term is the final overall map reading taking each of the five parameters into account (Figure BAD).

The software also uses anterior and posterior corneal elevation data to detect irregularities relative to both a standard best-fit-sphere, calculated at a fixed optical zone of 8.0mm, and relative to an enhanced best-fit-sphere, also calculated for an optical zone of 8.0mm, but excluding a 3.5mm zone centred on the thinnest point of the cornea (enhanced reference surface) (Figure B1) leaving out the central 3.5mm of elevation data. In eyes with keratoconus or related conditions the steepened cone can have the effect of steepening the best fit sphere, making the early stages of the condition less obvious. Eliminating the central cone from the BFS computation prevents the steepening of the best-fit sphere and increases its sensitivity, said Michael Belin MD, Tucson, Arizona PhD, Albany Medical Center, Albany, New York, who developed the enhanced best-fit sphere for the BAD display.

“The best analogy is a topographic map of the earth, where we use sea-level as a reference surface for elevation. If we were to use an average of all the elevation data, as we do in corneal topography, the reference surface would get higher and the mountains would get lower. By, in effect, eliminating the mountains from the best fit sphere calculation, we mimic sea level in our enhanced best-fit sphere, making the cones easier to see,” Dr Belin explained.

He noted that in Dr Salomão's study the pachymetric profiles of topographically normal contralateral eyes of keratoconus patients on their own detected keratoconic abnormalities in 89 per cent of cases. Elevation based on the enhanced best-fit sphere detected anterior abnormalities in 16 per cent and posterior abnormalities in 79 per cent, raising the overall finding of keratoconic abnormalities to 98 per cent.

“In almost every case Dr Ambrósio and I have looked at – and we are talking about databases of thousands – changes were either greater on the posterior surface or only present on the posterior surface so the posterior surface is a much more sensitive indicator than the anterior surface,” Dr Belin said.

renatoambrosiojr@terra.com.br
MWBelin@aol.com